

An Alternative to Traditional Denture Prostheses

Cooperation is key in creating customized, CAD/CAM-fabricated restorations that blend the properties of zirconia substructure with those of layered porcelain.

By Stan Lott, CDT

By combining a precise and lasting fit with dependable function for a lifetime, implant-supported fixed prostheses have gained acceptance among dentists and laboratory technicians.¹ High-strength, customized zirconia substructures fitted with pressed all-ceramic tooth restorations and fabricated with computer-aided design/computer-aided manufacturing (CAD/CAM) technology provide edentulous patients with a highly esthetic and durable alternative to conventional denture prostheses.

Paramount to the success of such treatments is communication among team members when considering the number of elements that affect a successful restoration.^{2,3} Laboratory technicians must take occlusal relationships, tooth shape and position, color, angulation, and patient expectations into account.^{4,5} The knowledge, artistic skill, and awareness of dental laboratory technicians allows them to blend the properties of the milled CAD/CAM zirconia substructure with the properties of layered porcelain.^{6,7}

Material Considerations

Zirconium oxide (IPS e.max[®] ZirCAD, Ivoclar Vivadent, www.ivoclarvivadent.com) can be used for the framework, which, once milled, is sintered with

temperatures up to 1,500°C to densify the microstructure, acquiring a final strength of 900 MPa.⁸ Its material hardness and inertness make it one of the strongest dental materials and ideal for implant substructures. For esthetic layering of the high-strength zirconia substructure, IPS e.max[®] Ceram demonstrates high bond strength, exact shade matching, and exceptional masking abilities.⁹⁻¹¹

Other materials that can be incorporated into such treatments are IPS e.max[®] Press lithium disilicate and IPS e.max[®] ZirPress. IPS e.max Press enables an exceptional fit and demonstrates a flexural strength of 400 MPa.^{12,13} IPS e.max ZirPress is specifically designed to press onto IPS e.max[®] ZirCAD frameworks and is indicated for zirconium oxide-supported gingiva portions, single-tooth restorations, anterior and posterior bridges, inlay-retained bridges, and implant superstructures.^{14,15}

When used in combination with the All-on-4[™] implant treatment concept (NobelActive[™], Nobel Biocare, www.nobelbiocare.com), full-arch zirconia substructures and pressed restorations provide edentulous patients with stable, functional, esthetic, and comfortable prostheses.¹⁶

Case Presentation

A 68-year-old woman presented with an existing maxillary denture and missing lower teeth. Diagnostic radiographs were taken, along with other records. A comprehensive treatment plan was discussed and agreed upon between patient and dentist to include extraction of the remaining lower teeth and an All-on-4 prosthesis. The fixed prosthesis would be fabricated using a CAD/CAM yttrium-stabilized zirconium-oxide block (IPS e.max ZirCAD) that would then be pressed over with highly esthetic

ceramic (IPS e.max ZirPress) in the gingival areas, and then restored with individual pressed-ceramic crowns (IPS e.max Press).

A combined zirconia and ceramic prosthesis would provide a better fit and finish than traditional denture materials. Additionally, the ceramic would promote greater biocompatibility and soft-tissue response based on its high polishability and smooth surface. To facilitate an ideal ridge width at the implant head, occlusal planing of the alveolar ridge would be performed (Figure 1). Before the extraction appointment, the tooth shade was selected to facilitate fabrication of the zirconia and pressed-ceramic prosthesis.

Clinical Protocol

Immediately after the extraction of the lower teeth, the implants (NobelActive)

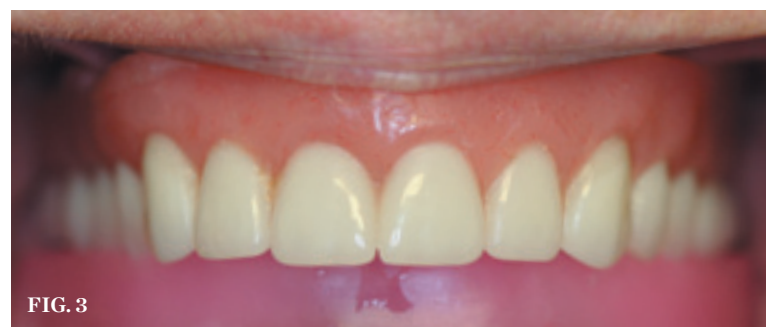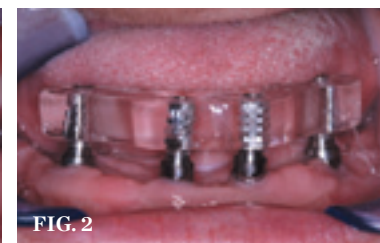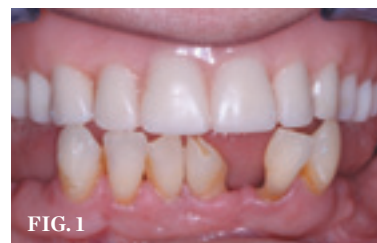were placed using the “All-on-4” technique. A fabricated surgical guide was used to correctly place the implants, and multi-unit transmucosal abutments were added to facilitate tissue-level emergence. If tissue depth exceeds 3 mm, and to facilitate good hygiene, transmucosal abutments are used to extend the seating platform of the metal framework 1 mm to 1.5 mm above the tissue height.



To read another article about Denture Prostheses, visit: dentalaegis.com/go/id254

The implant impression copings were placed and luted together with Pattern Resin[™] LS (GC America, www.gcamerica.com). Next, an impression was made from which to fabricate the master cast. A laboratory verification jig was designed from the master cast to ensure an accurate fit of the final substructure (Figure 2). The mandibular tooth function and arrangement were evaluated using an occlusal wax rim (Figure 3). Basic tooth set-up was determined from tooth Nos. 19 through 30 using the anterior-posterior spread.

After the set-up was screwed in during an office visit, the patient's bite was verified, and phonetics, function, and esthetics were approved. Proper



CLINICAL SITUATION (1.) Retracted view of the patient's preoperative condition. **(2.)** A laboratory verification jig was used to verify the fit of the master cast substructure. **(3.)** An occlusal wax rim was used to evaluate the arrangement and function of the mandibular teeth.



STAN LOTT, CDT
Owner
Precision Dental Arts
Twin Falls, Idaho

vertical and anterior and posterior positioning were verified with a bite registration. A stick bite was also obtained to confirm the horizontal positioning of the set-up. After the creation of a silicone matrix, metal temporary abutments were used as provisional restorations.

Laboratory Protocol

The substructure was created and placed on an articulator for scanning with a high-accuracy, 3D CAD/CAM laser scanner (Optimat 3D scanner, Nobel Biocare). The zirconia substructure was then designed using the CAD/CAM software (Figure 4), after which the zirconia framework was CAM-milled (Figure 5).^{14,17} The scanned and milled substructure accommodates the IPS e.max Press restorations and the IPS e.max ZirPress gingival ceramics, and would serve to restore the lost vertical of the alveolar bone process and teeth.¹⁸

A full-contour wax-up was done of the 12 individual IPS e.max Press restorations. As a precautionary measure,

the choice was made *not* to blast the zirconia framework with aluminum particles in order to prevent damage.

To ensure a predictable bond, a thin layer of bonding liner material (ZirLiner, Ivoclar Vivadent) was applied to the substructure. This liner also served to augment the depth of color. IPS e.max gingival stains Berry and Rose were added to enhance the esthetics of the gingival areas (Figure 6). Once the stains were dry, the substructure was fired.

A silicone matrix of the tooth set-up was used to inject wax onto the zirconia substructure in order to copy vertical, midline, and tooth arrangement. The exact dimensions would then be incorporated into the final IPS e.max Press restorations. To use the full 400 MPa strength of lithium disilicate, a slight cut-back and ceramic layering technique was used on the anterior teeth only.

Seating

The 12 individual IPS e.max crown restorations were stained and glazed, then

re-seated onto the zirconia substructure, and a final hand waxing of the gingival tissue architecture was performed (Figure 7). The 12 crown restorations were removed before the substructure was sprued, invested, and pressed with IPS e.max ZirPress Gingiva 3 (Figure 8 and Figure 9). The substructure was divested, cleaned, and separated from the sprues prior to staining and glazing. To finish, 10 of the 12 crowns were bonded onto the completed zirconia substructure (Figure 10), and then a final cleaning and polishing was performed (Figure 11). The prosthesis was delivered to the dentist's office, where it was torqued to the patient's implants (Figure 12). The final two bicuspid crowns were then bonded to the substructure

Conclusion

The advent of CAD/CAM technology and strong, versatile materials such as zirconia and pressable and milled ceramics make it easier for dentists to provide edentulous patients with highly

esthetic, durable, and stable prostheses.^{14,17,18} Coordinated planning among dentists, laboratory technicians, and implant surgeons is of utmost importance when executing an implant-supported restoration. This case demonstrates the organized planning and performance of a skilled dental team when delivering a successful IPS e.max Press and IPS e.max ZirCAD high-strength restoration to satisfy a patient's demands for esthetics, strength, and comfort.



For product information on
Denture Prostheses, visit:
dentalaegis.com/go/id255

Acknowledgments

Mr. Lott would like to acknowledge Dr. Charley Varipapa of Alexandria, Virginia, and Dr. Chris Mazzola, AACD, of Sun Valley, Idaho, who helped him develop much of this technique. He would also like to thank Dr. Brandon Williams for treating this case, as well as Jordan Lott for the photography, and Jason Boyce, Brian Smith,

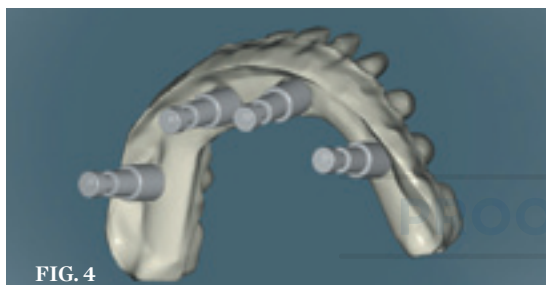


FIG. 4

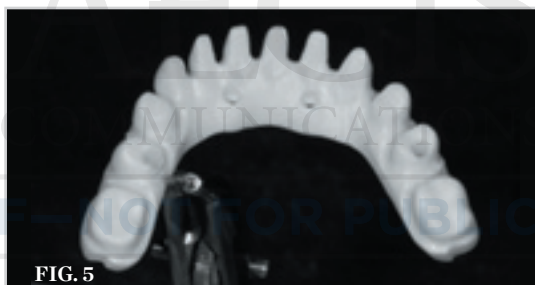

FIG. 5

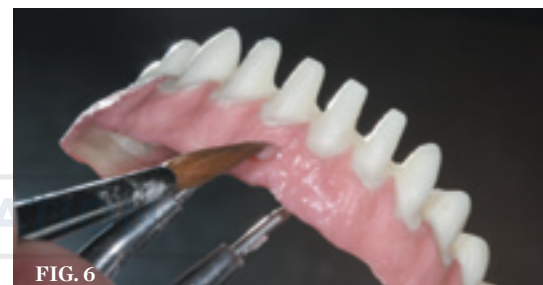

FIG. 6

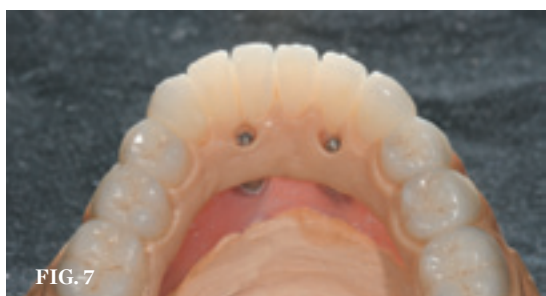

FIG. 7

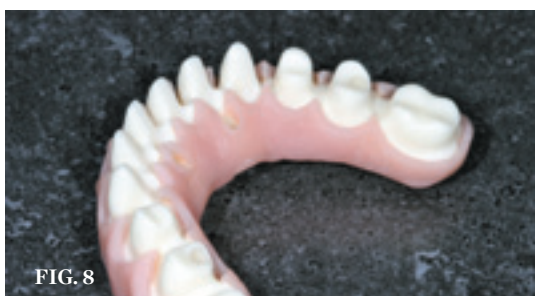

FIG. 8

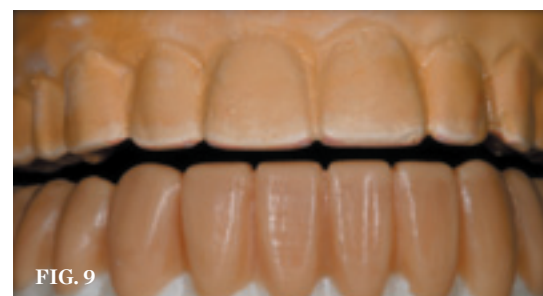

FIG. 9

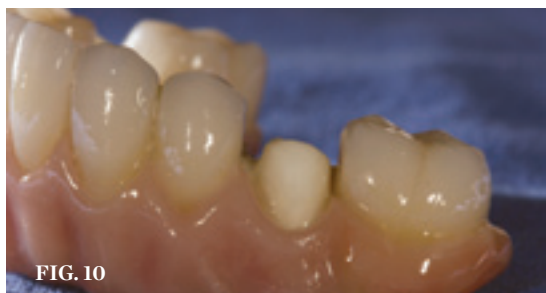

FIG. 10

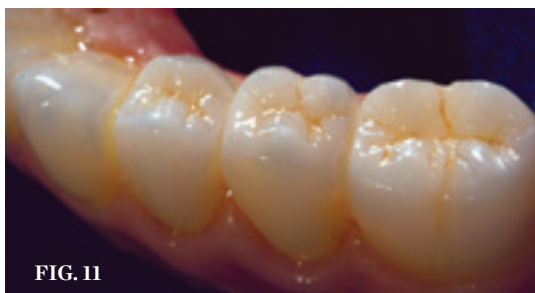

FIG. 11

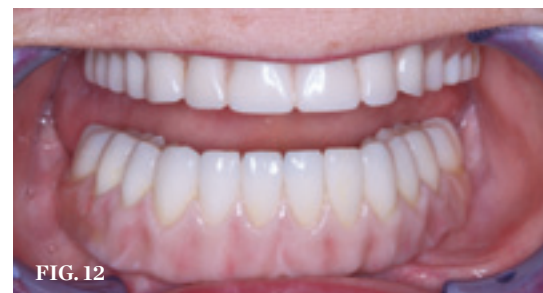

FIG. 12

LABORATORY PHASE (4.) The zirconia substructure was designed using advanced CAD/CAM software. **(5.)** The zirconia framework was milled using CAD/CAM technology. **(6.)** ZirLiner was applied to the gingival areas and enhanced with Berry and Rose e.max gingival stains. **(7.)** Tissue architecture after the final hand waxing was performed. **(8.)** View of the substructure with crowns removed. **(9.)** The substructure was sprued, invested, and pressed with IPS e.max Gingiva 3. **(10.)** Ten of the 12 tooth restorations were bonded into place on the zirconia substructure. **(11.)** The prosthesis was cleaned and polished before delivery. **(12.)** The finished prosthesis was torqued onto the patient's implants and the final two bicuspids were bonded to the substructure.

and Jordan Lott for their collaboration.

J Adhes Dent. 2006;8(6):427-431.

References

1. Rossein KD. Alternative treatment plans: implant supported mandibular dentures. *Inside Dentistry.* 2006;2(6):42-43.
2. Friebel M, Povel K, Cappius HJ, et al. Optical properties of dental restorative materials in the wavelength range 400 to 700 nm for the simulation of color perception. *J Biomed Opt.* 2009;14(5):054029.
3. Carlson RS. Dental artistry. *Gen Dent.* 2003; 51(4):326-330.
4. Giordano R. A comparison of all-ceramic restorative systems. *J Mass Dent Soc.* 2002; 50(4):16-20.
5. Magne P, Douglas WH. Porcelain veneers: dentin bonding optimization and biomimetic recovery of the crown. *Int J Prosthodont.* 1999;12(2):111-121.
6. Roediger M, Gersdorff N, Huels A, Rinke S. Prospective evaluation of zirconia posterior fixed partial dentures: four-year clinical results. *Int J Prosthodont.* 2010;23(2):141-148.
7. Khang L. Understanding zirconia backgrounds for custom shade matching. *J Cosmet Dent.* 2009;24(4):94-100.
8. Ivoclar Vivadent. *IPS e.max ZirCad: Instructions for Use.* (2010). [Brochure]. Schaan, Liechtenstein.
9. Ivoclar Vivadent. *IPS e.max Ceram: Instructions for Use.* (2009). [Brochure]. Amherst, NY.
10. Aboushelib MN, Dozic A, Liem JK. Influence of framework color and layering technique on the final color of zirconia veneered restorations. *Quintessence Int.* 2010;41(5):e84-89.
11. Luo XP, Zhang L. Effect of veneering techniques on color and translucency of Y-TZP. *J Prosthodont.* 2010;19(6):465-470.
12. McLaren EA, Phong TC. Ceramics in dentistry—part 1: classes of materials. *Inside Dentistry.* 2009;5(9):94-103.
13. Tysowsky GW. The science behind lithium disilicate: a metal-free alternative. *Dent Today.* 2009;28(3):112-113.
14. Helvey GA. Chairside CAD-CAM. lithium disilicate restoration for anterior teeth made simple. *Inside Dentistry.* 2009;5(10):58-66.
15. Ivoclar Vivadent. *IPSe.max—one system for every indication.* (2009). [Brochure]. Amherst, NY.
16. Malo P, de Araujo Nobre M, Lopes A, et al. A longitudinal study of the survival of All-on-4 implants in the mandible with up to 10 years of follow-up. *J Am Dent Assoc.* 2011;142(3):310-320.
17. Reynolds JA, Roberts M. Lithium-disilicate pressed veneers for diastema closure. *Inside Dentistry.* 2010;6(5):46-52.
18. Sorensen JA, Cruz M, Mito WT, et al. A clinical investigation on three-unit fixed partial dentures fabricated with a dual-curing adhesive system and a self-curing resin cement.

